

Sarcomatoid urothelial carcinoma with chondrosarcomatous differentiation of the bladder: a case report

Sarcomatoid urothelial carcinoma

Recep Bedir
Department of Pathology, Recep Tayyip Erdogan University, Medical Faculty, Rize, Turkey

Abstract

Sarcomatoid urothelial carcinoma with chondrosarcomatous differentiation of the urinary bladder is a rare tumor. This tumor, known as carcinosarcoma has a poor prognosis. The present study reports a rare case of sarcomatoid urothelial carcinoma with chondrosarcomatous differentiation in the bladder of a 71-year-old man.

Keywords

Bladder; Sarcomatoid Carcinoma; Chondrosarcomatous Differentiation

DOI:10.4328/ACAM.6006 Received: 17.08.2018 Accepted: 17.09.2018 Published Online: 20.09.2018 Printed: 01.07.2019 Ann Clin Anal Med 2019;10(4): 522-4
Corresponding Author: Recep Bedir, Department of Pathology, Recep Tayyip Erdogan University of Medical Faculty, Rize, Turkey.
T.: +90 4642130491 GSM: +905057331695 E-Mail: bedirrecep@gmail.com
ORCID ID: <https://orcid.org/0000-0001-8247-3781>

Introduction

Sarcomatoid urothelial carcinoma is a very rare variant of urothelial carcinoma and it is generally detected in the bladder [1]. It constitutes 0.2-0.6% of all the histological subtypes of urothelial carcinomas found in bladder [2]. The malign heterogeneous elements such as chondrosarcoma and osteosarcoma may accompany these tumors, which are also known as carcinosarcoma [3]. The prognosis of these tumors having an aggressive course is worse than other urothelial carcinomas [4]. In the present study, we present a 71-year-old male patient's sarcomatoid urothelial carcinoma with chondrosarcomatous differentiation detected in bladder transurethral resection (TUR) material which is rarely seen.

Case Report

A 71-year-old male patient applied to our clinic with the complaint of hematuria for 15-20 days. In computed tomography (CT) imaging, a mass infiltrating the bottom-right edge of the urethra, extending towards adjacent fatty tissues, and having 8x4cm size was found in the right posterior wall of the bladder. The patient underwent TUR. In the macroscopic analysis of TUR material with 15x10x7cm size, the high-grade urothelial carcinoma foci consisting of papillary structures and the sarcomatoid zones showing differentiation towards chondrosarcoma consisting of spindle mesenchymal cells with the apparent nucleolus and large hyperchromatic nucleus, and having a pleomorphic appearance with highly mitotic activity were observed (Figure 1-3). In addition, the tumor was observed an undifferentiated element composed of small cells (Figure 4). No invasion analysis could be performed since no muscularis propria was observed in the tumor. In immunohistochemical analysis, the positive staining with both cytokeratin 7 (CK7) and vimentin were observed in sarcomatoid areas and positive staining with S-100 in chondrosarcomatous areas. Based on these findings, the case was diagnosed with invasive sarcomatoid urothelial carcinoma with chondrosarcomatous differentiation. Since the patient didn't accept the surgical therapy, he received chemotherapy for only 3 months and then died 1 year later because of widespread metastases. The written informed consent was obtained from the patient before the aforementioned work was carried out.

Discussion

Sarcomatoid urothelial carcinoma is a different histologic variant of urothelial carcinoma and the term "invasive urothelial carcinoma, sarcomatoid variant" was preferred in the 2004 World Health Organization Classification Tumors of the Urinary System [5]. The risk of metastasis is high in urothelial carcinomas with sarcomatoid differentiation and the most frequently seen metastases are those in bones, liver, lung, and lymph nodes [6]. The large majority of these tumors are histologically high-grade [7]. In sarcomatoid carcinomas, the metaplastic changes such as chondroid and osseous metaplasia or the more aggressive histological findings such as pseudo-carcinomatous stroma may be seen [4]. In these tumors, the epithelial component consists of urothelial carcinoma, urothelial carcinoma in situ, small-cell carcinoma, adenocarcinoma, and squamous cell carcinoma, whereas the sarcomatous component consists of

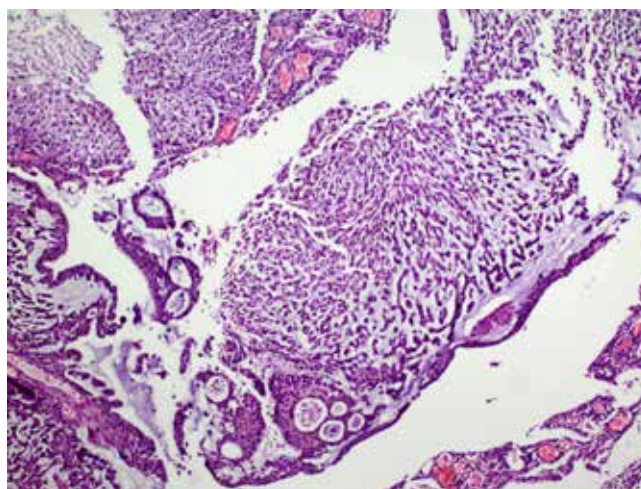


Figure 1. Tumor showing epithelial and sarcomatoid component (H&Ex100)

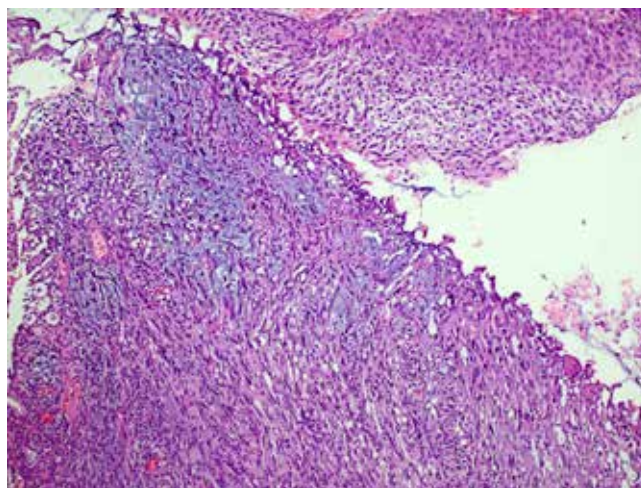


Figure 2. Tumor showing sarcomatoid carcinoma component with chondrosarcomatous differentiation (H&Ex200)

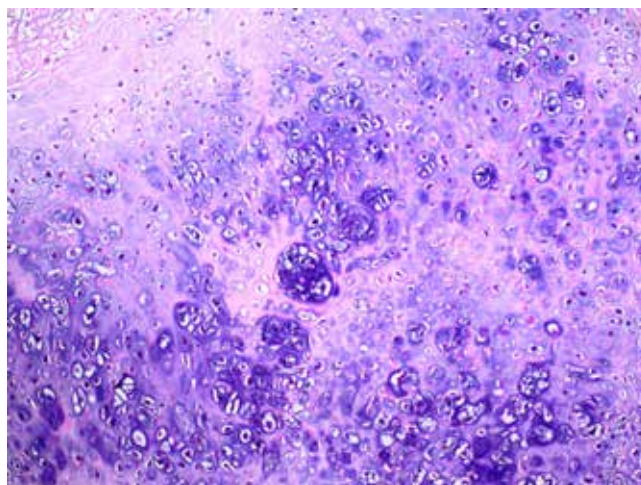


Figure 3. Tumor showing well-differentiation chondrosarcomatous areas (H&Ex200)

leiomyosarcoma, chondrosarcoma, and osteosarcoma [5]. The differential diagnosis of these tumors includes the pseudo-sarcomatous stromal reaction with low mitotic activity and minimal atypia but deficit in apparent malignancy criteria.

In these tumors having bad prognosis resistant to radiotherapy, the main therapy option is surgical resection and it is recommended to perform total cystectomy. The adjuvant radiotherapy and chemotherapy were observed to have no positive effect on the prognosis [7-9]. Since he denied surgical therapy, our patient received only the chemotherapy.

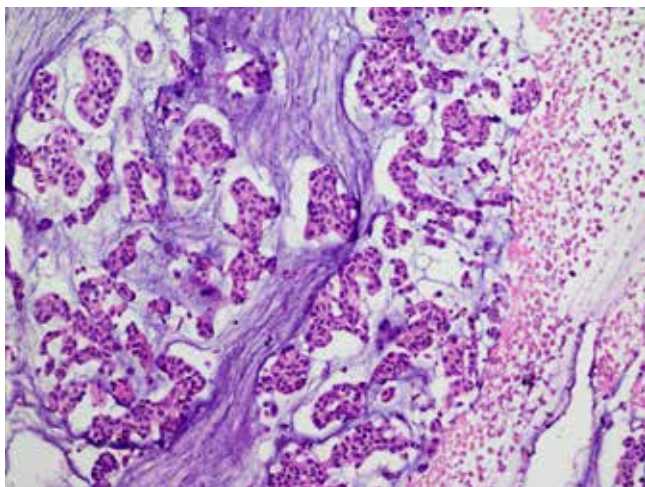


Figure 4. Tumor showing undifferentiated chondrosarcomatous areas (H&E x200)

In conclusion, understanding the sarcomatoid urothelial carcinoma is important from therapeutic and prognostic aspects. These tumors should be accepted as high-grade invasive urothelial carcinoma with a high level of sarcomatous differentiation, which may include malign heterologous components such as chondrosarcoma. The pseudosarcomatous stromal reaction, which may be confused with these tumors in the histopathological analysis, should be kept in mind.

Scientific Responsibility Statement

The authors declare that they are responsible for the article's scientific content including study design, data collection, analysis and interpretation, writing, some of the main line, or all of the preparation and scientific review of the contents and approval of the final version of the article.

Animal and human rights statement

All procedures performed in this study were in accordance with the ethical standards of the institutional and/or national research committee and with the 1964 Helsinki declaration and its later amendments or comparable ethical standards. No animal or human studies were carried out by the authors for this article.

Conflict of interest

None of the authors received any type of financial support that could be considered potential conflict of interest regarding the manuscript or its submission.

References

1. Lu W, Wang Y, Li Y, Cao Y, Han H, Zhou F. Sarcomatoid urothelial carcinoma with chondrosarcomatous differentiation of the ureter: A case report and review of the literature. *Oncol Lett.* 2017; 13: 1331-7.
2. Cho MH, Kim SH, Park WS, Joung JY, Seo HK, Chung J, et al. Bladder chondrosarcoma plus urothelial carcinoma in recurred transitional cell carcinoma of the upper urinary tract: a case report and literature review. *World J Surg Oncol.* 2016; 20: 270.
3. Darko A, Das K, Bhalla RS, Heller D. Carcinosarcoma of the ureter: Report of a case with unusual histology and review of the literature. *Int J Urol.* 2006; 13: 1528-31.
4. Nicolas MM, Nazarullah A, Guo CC. Sarcomatoid urothelial carcinoma with chondrosarcomatous differentiation of the ureter: A case report. *Anal Quant Cytopathol Histopathol.* 2014; 36: 111-16.
5. Eble JN, Sauter G, Epstein J, Sesterhenn I, editors. World Health Organization Classification of Tumours: Pathology and Genetics of Tumours of the Urinary System and Male Genital Organs. 3rd ed Vol. 7. Lyon: IARC Press; 2004.
6. Johnin K, Kadowaki T, Kushima M, Ushida H, Koizumi S, Okada Y. Primary het-

erologous carcinosarcoma of the ureter with necrotic malignant polyps. Report of a case and review of the literature. *Urol Int.* 2003; 70: 232-5.

7. Perimenis P, Athanasopoulos A, Geraghty J, Speakman M. Carcinosarcoma of the ureter: A rare, pleomorphic, aggressive malignancy. *Int Urol Nephrol.* 2003; 35: 491-3.

8. Wang X, MacLennan GT, Zhang S, Montironi R, Lopez-Beltran A, Tan PH, et al. Sarcomatoid carcinoma of the upper urinary tract: Clinical outcome and molecular characterization. *Hum Pathol.* 2009; 40: 211-17.

9. Yilmaz E, Birlik B, Arican Z, Guney S. Carcinosarcoma of the renal pelvis and urinary bladder: A case report. *Korean J Radiol.* 2003; 4: 255-9.

How to cite this article:

Bedir R. Sarcomatoid urothelial carcinoma with chondrosarcomatous differentiation of the bladder: a case report. *Ann Clin Anal Med* 2019;10(4): 522-4.